

R2P in Action: Real Case, Real Impact

A case example highlights the utility of Terumo’s R2P System for complex peripheral artery disease.

By Sameh Sayfo, MD, MBA, FSCAI, FACC

PATIENT PRESENTATION

A woman in her mid 60s with a past medical history of coronary artery disease, type 2 diabetes mellitus, and peripheral artery disease with previous left superficial femoral artery (SFA) stenting presented to the outpatient clinic with progressive life-limiting claudication (Rutherford class 3/4). Outpatient workup including ankle-brachial index (ABI) and arterial ultrasound revealed an ABI of 0.35 and an occluded SFA stent with reconstitution at the popliteal level. The patient failed medical therapy and walking exercise; due to progression to Rutherford class 4, peripheral angiography was performed.

Ultrasound-guided right radial artery access was achieved using a short 5/6-F Glidesheath Slender® (Terumo Interventional Systems). The aortic arch was navigated using a 5-F, 125-cm JR4 catheter, which was advanced to the left external iliac artery (EIA), where a selective angiogram was obtained. Angiography

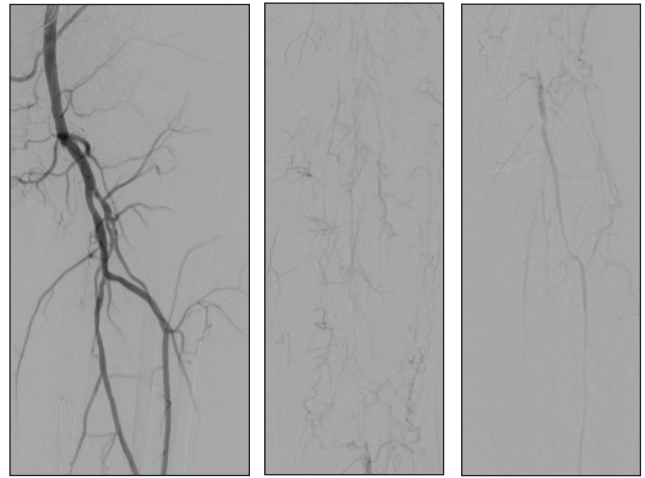


Figure 1. Diagnostic angiograms showing the long chronic total occlusion in the SFA, with in-stent restenosis that reconstituted at the distal SFA with single-vessel runoff.

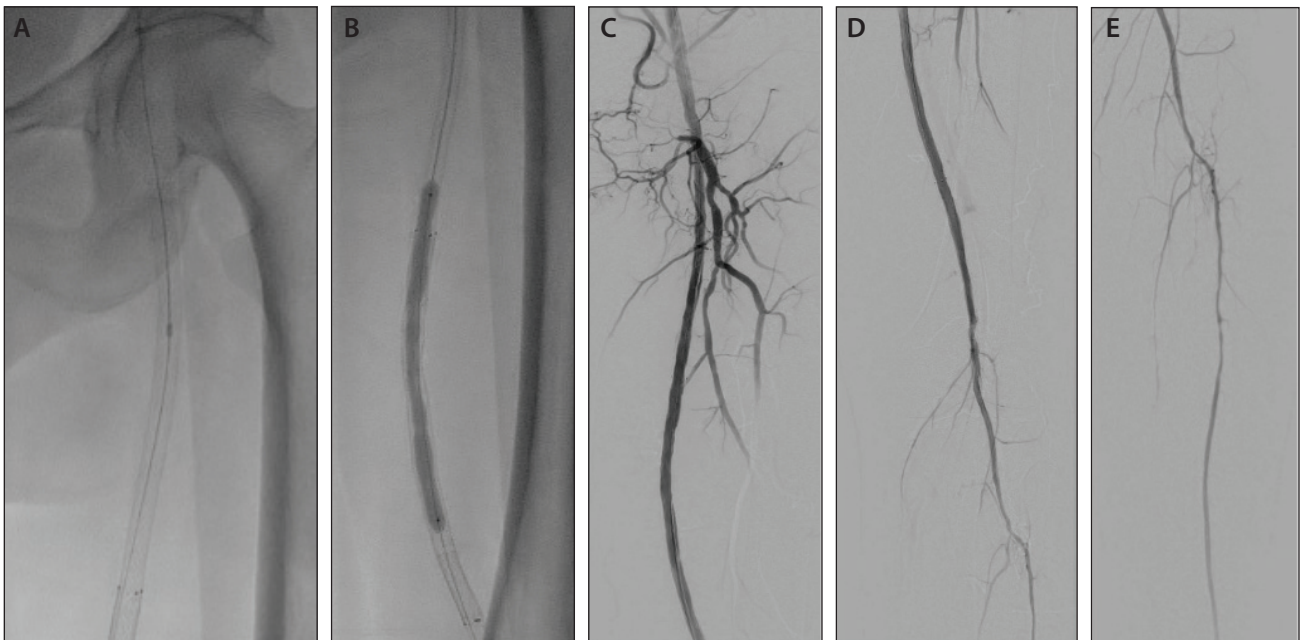


Figure 2. Laser atherectomy using a 1.5-mm Auryon laser followed by balloon percutaneous transluminal angioplasty using the 5- X 100-mm R2P® Crosstella® balloon (A) followed by inflation of a 5- X 150-mm In.Pact Admiral DCB (B). Final angiography showed 0% residual stenosis, with a patent SFA and popliteal artery, single-vessel runoff, and no complications (dissection or distal embolization) (C-E).

RADIAL ACCESS REIMAGINED

Sponsored by Terumo Interventional Systems

revealed an occluded SFA from the ostium, as well as reconstitution at the adductor canal (Figure 1).

PROCEDURAL OVERVIEW

Using a long, stiff Hi-Torque Supra Core guidewire (Abbott), a long 6-F, 119-cm R2P® Destination Slender® sheath (Terumo Interventional Systems) was advanced to the left EIA. The lesion was navigated by a 200-cm R2P® NaviCross® microcatheter (Terumo Interventional Systems) and an 0.018-inch Glidewire® Advantage®

(Terumo Interventional Systems), which was swapped with a 475-cm ViperWire (Abbott) upon crossing the distal cap. Laser atherectomy using a 1.5-mm Auryon XL laser (AngioDynamics) was performed, with excellent results (Figure 2). Next, balloon angioplasty was performed using a 5- X 100-mm R2P® Crosstella® balloon (Terumo Interventional Systems), followed by 3-minute inflation of a 5- X 150-mm In.Pact Admiral drug-coated balloon (DCB). The final angiogram revealed 0% residual stenosis, with single-vessel runoff. ■